

## Supplementary Data

---

# Lost and Forgotten? Orientation Versus Memory in Alzheimer's Disease and Frontotemporal Dementia

Belinda Yew<sup>a</sup>, Suvarna Alladi<sup>d</sup>, Mekala Shailaja<sup>d</sup>, John R. Hodges<sup>a,b,c</sup> and Michael Hornberger<sup>a,b,c,\*</sup>

<sup>a</sup>*Neuroscience Research Australia, Sydney, Australia*

<sup>b</sup>*Faculty of Medicine, University of New South Wales, Sydney, NSW, Australia*

<sup>c</sup>*ARC Centre of Excellence in Cognition and its Disorders, Sydney, NSW, Australia*

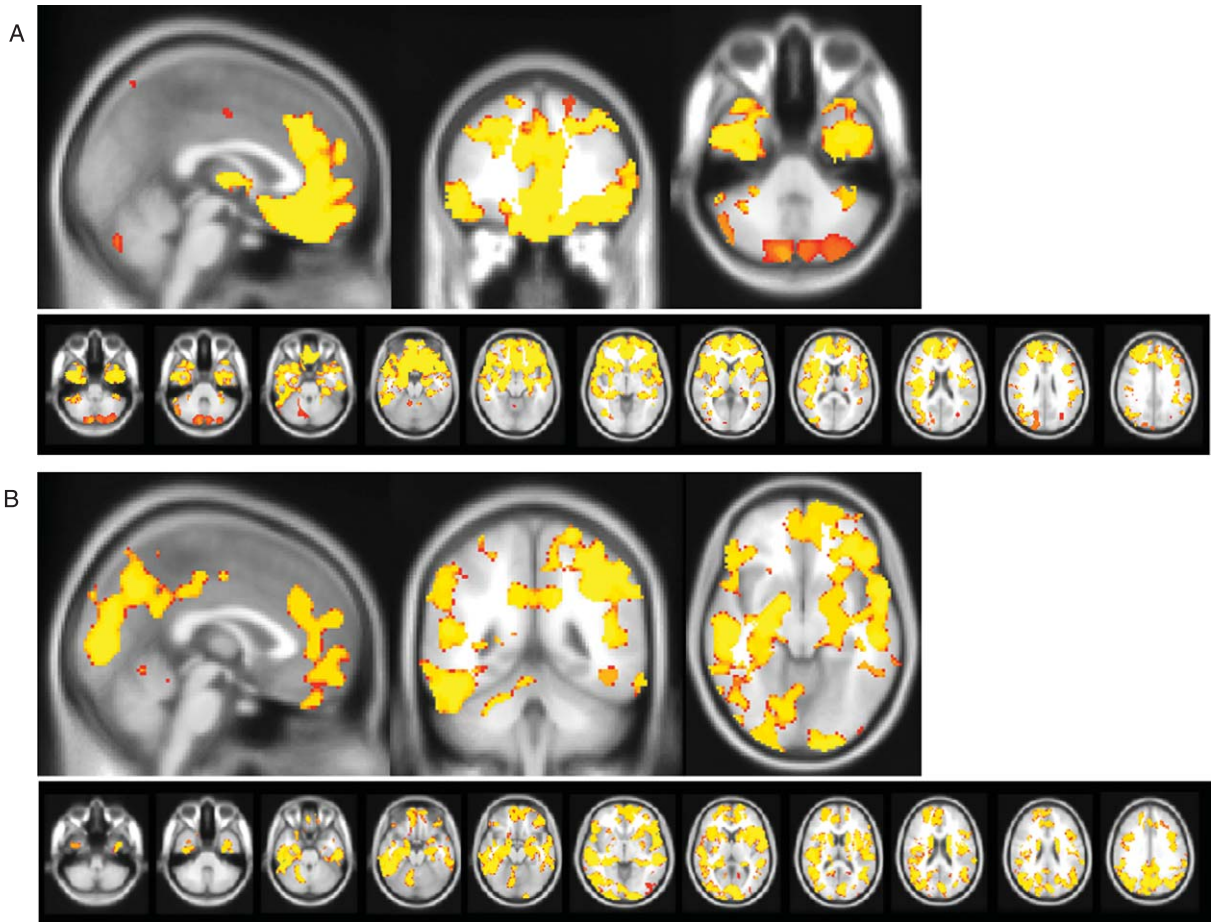
<sup>d</sup>*Department of Neurology, Nizam's Institute of Medical Sciences, Hyderabad, India*

Handling Associate Editor: Paulo Caramelli

Accepted 9 August 2012

---

\*Correspondence to: Dr. Michael Hornberger, Neuroscience Research Australia, Sydney, Randwick, NSW 2031, Australia. Tel.: +61 2 9399 1816; E-mail: m.hornberger@neura.edu.au.



Supplementary Figure 1. Brain atrophy patients compared to controls. Voxel-based morphometry analyses showing grey matter atrophy for a) bvFTD versus controls and b) AD versus controls. Clusters are overlaid on the MNI standard brain ( $t > 2.41$ ). Colored voxels show regions that were significant in the analyses for  $p < 0.05$  family-wise error corrected.